



## Parathyroid Adenoma Located on Anterior Mediastinum and Hungry Bone Syndrome; Case Report

### Anterior Mediasten Yerleşimli Paratiroid Adenomu ve Aç Kemik Sendromu; Olgu Sunumu

Mediastinal Paratiroid Adenomu / Mediastinally Parathyroid Adenoma

Ali Çelik, Ertan Aydın, Ülkü Yazıcı, Nurettin Karaođlanođlu  
Atatürk Center For Chest Disease and Thoracic Surgery Department of Thoracic Surgery, Kecioren, Ankara, Türkiye

This paper was presented at TUSAD 32. national congress as a electronic poster (EP-131) in Antalya, 20-24 Oct 2010

#### Özet

Anterior mediasten, ektopik paratiroid adenomu için nadir bir lokalizasyondur. Primer hiperparatroidi (PHP) etyolojisi araştırılan hastalarda ortalama % 1-2 oranında görülmektedir. Otuz üç yaşında PHP etyolojisi nedeniyle araştırılan erkek hastada, Technetium-99m-methoxyisobutylisonitrile (Tc-99m MIBI) sintigrafisi ile ektopik paratiroid dokusuna işaret eden, anterior mediastinal lezyon saptandı. Sternotomi ile total kitle eksizyonu yapıldıktan sonra patoloji sonucu paratiroid adenomu olarak raporlandı. Postoperatif erken dönemde aç kemik sendromu gelişen, uygun tedavi sonrası klinik bulguları ve laboratuvar değerleri normale dönen hasta sorunsuz şekilde taburcu edildi. Bu olgu nedeniyle mediasten yerleşimli ektopik paratiroid adenomlarında cerrahi seçenekleri ve postoperatif takibi literatür bilgileri ışığında gözden geçirildi.

#### Anahtar Kelimeler

Ektopik Paratiroid Adenomu; Anterior Mediasten; Aç Kemik Sendromu

#### Abstract

Anterior mediastinum is a rare localization for ectopic parathyroid adenoma. This localization seen about 1-2 % in the patient that looked for primary hyperparathyroidism etiology. On a 33 - years old male patient who had searched for primary hyperparathyroidism etiology, an anterior mediastinal lesion which referred to be an ectopic parathyroid adenoma was detected via Tc-99m MIBI. After, total mass excision was performed via sternotomy, pathologic examination reported as parathyroid adenoma. In early postoperative period, hungry bone syndrome was occurred. After treatment, the patient whose clinic and laboratory results was normal discharged uneventful. The ectopic paratiroid adenomas and their surgical options and postoperative management has reviewed with literature knowledge due to this case.

#### Keywords

Ectopic Parathyroid Adenoma; Anterior Mediastinum; Hungry Bone Syndrome; Surgery

DOI: 10.4328/JCAM.769

Received: 04.08.2011

Accepted: 09.08.2011

Printed: 01.01.2014

J Clin Anal Med 2014;5(1): 69-71

Corresponding Author: Ali Celik, Atatürk Center For Chest Disease and Thoracic Surgery, Department of Thoracic Surgery, Kecioren, 06280, Ankara, Turkey.

GSM: +905304045467 F.: +90 3123552135 E-Mail: alicelik78@gmail.com

**Introduction**

Parathyroid adenomas causing to hyperparathyroidism may present an ectopic localization at 20-25% of the patients [1]. These ectopically located adenomas are seen by mean 5-10% at posterior mediasten; 20% at substernal localization and about 1-2% at anterior mediasten and at the lower levels from manubrium. Particularly the lesions located below manubrium can not be reached with cervical exploration. Presence of the mediasten located parathyroid adenoma usually indicates the presence of high than normal number of parathyroid gland. Persisting high calcium levels at postoperative period are related to ectopic and/or high than normal number of parathyroid gland. Therefore postoperative evaluation affects the surgical outcome. Localization should be defined through the methods such as Tc-99m MIBI or Single Photon Emission Computed Tomography (SPECT) and the appropriate surgery should be performed.

**Case Report**

At the laboratory outcomes of a 33 years old male patient which was studied with pain complaint at bilateral lower extremities and had not any obvious pathology at the physical examination; calcium (Ca+) levels were defined as 15.9 mg/dl; phosphorus levels as 2.1 mg/dl and parathyroid hormone (PTH) levels as 1500 pg/ml. Bone densitometry measurement (Z score: -2.8) was found to be consistent with osteoporosis (Figure 1). On parathyroid scintigraphy performed with Tc99-m MIBI; activity involvement that observed at the early period was seen to persist also at the late period (Figure 2a). On computerized tomography; 36x15x15 mm sized; with similar density to thyroid gland and may belong to ectopic thyroid or parathyroid gland; well circumscribed and smooth contoured solid lesion was reported (Figure 2b). In addition there were well counted cystic lesions at the right humeral head and the right clavicle. Several lytic appearance expansile lesions were identified at the right third rib lateral arch (Brown tumor). There was medullary expansion due to bone marrow hyperlasia at the sternum and thinning at the cortex. The patient with Ca+ values regressed to normal limits after appropriate hidration was taken to the operation. 3x2 cm solid structured thymus tissue at the mediasten was totally excised together with pericardial and substernal fat tissue through sternotomy. Parathyroid adenoma was reported following the pathology. While PTH levels were 120 pg/ml; Ca+ 8.1 mg/dl and phosphorus 3.0 mg/dl at postoperative first hour; control values came as Ca+ 5.1 mg/dl; PTH 430 pg/ml and phosphorus 2.0 mg/dl after 6 hours. Ca+ replacement was controlledly ad-

ministered to the patient along 4 days considering hungry bone syndrome. The patient without any problem in follow-up was discharged at postoperative 8th day.

**Discussion**

PTH and Ca+ levels of PHP patients are above the normal limits and there is no a secondary pathology will cause this height. The symptoms and findings at these patients are seen after increasing of blood levels due to Ca+ destruction from the bones and simultaneously increasing of Ca+ excretion with the urine. Hypercalciuria and concomitant renal calculus occurrence; bone diseases seen after decreasing of Ca+ levels (for example: bone cysts; osteitis fibrosa cystica; Brown tumor; bone fractures and pains); gasrtointestinal system patalogies associated with the severity of hypercalciuria (for example: anorexia; weight loss; nausea; vomiting) and skeletal muscle system patalogies may be seen at PHP.

While primary hyperthyroidism is developed due to solitary parathyroid adenoma at 80% of the patients; parathyroid hyperlasia and parathroid cancers are the reasons of PHP at other patients [1]. Parathyroid adenomas usually develop from the glands that are in normal number and location. Gilmour et al. [2] have stated that parathyroid glands that are four at 80% of patients; may be more or less than four at the rest 20% of patients. When there are parathyroid glands more than normal number; one of them usually locates at mediasten and adenomas developed from these glands is called mediasten located adenoma. Parathyroid adenomas may be found in the deep mediasten localization in 2% of the cases [3]. In addition; there may be rarely ectopic localization at visceral mediastinal compartment; aortopulmonary window; paraesophageal localization or subcarinal region. Since the number of parathyroid glands can change and they may located in a such wide area; location of the lesion requires a good understanding at the patients that surgery is planned. Ultrasound; Tc99-m MIBI scintigraphy; SPECT and magnetic resonance imaging (MRI) are the most common used methods among the noninvasive tests. The most common used method for today is Tc99-m MIBI scintigraphy. However while Tc99-m MIBI has a sensitivity of 78% at hyperparathyroidism; sensitivity of SPECT is 96%. Furthermore while lesions less than 1 gr can be easily identified with SPECT; outcomes of Tc99-m MIBI are related to gland size and Ca+ levels. It may not detected the minor glands [4]. However Tc99-m MIBI has become the most used method because it is usually insufficient to define the lesions and that SPECT is not available at

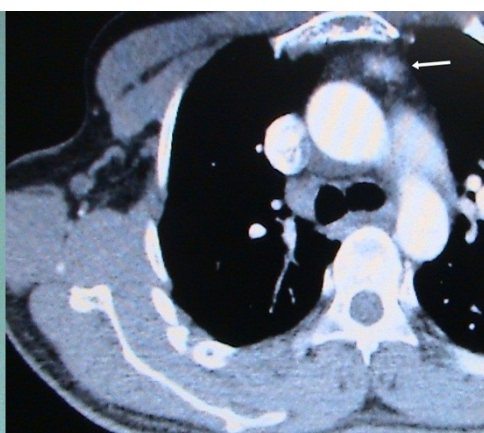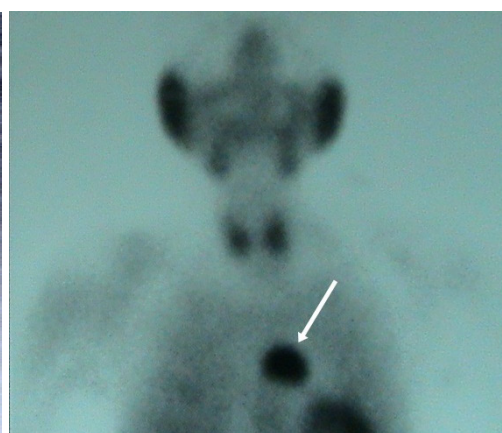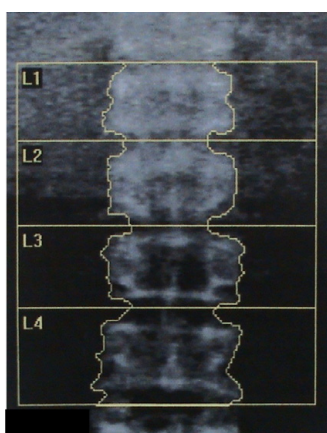


Figure 1. Display at L2 – L4 levels of bone densitometry consistent with osteoporosis (Z score: - 2.8) Figure 2. Display of activity (arrow) involvement at anterior mediasten on Tc99-m MIBI (A) 36x15x15 mm sized; well-circumscribed; smooth countoured solid lesion (arrow) at similar density with thyroid gland (B)

many of the centers. Sensitivity of CT and MRI for mediastinal located adenomas is 42- 68% and 77- 82% respectively [5]. Although ultrasound usually is a practical method for lesions at cervical region; its sensitivity at mediastinal located lesion is 12- 18% [3]. For radiological studies at recurrent parathyroid adenomas; Johnson et al. have found positive predictive values as 60- 92% for ultrasound; 78- 100% for Sestamibi; 36- 100% for CT; 51- 100% for MRI and 70- 74% for PET [6].

Proper surgical approach at anterior mediastinal located lesions differs as to location of the lesion and experience of the surgeon. The lesion can be reached through thoracoscopic surgery (VATS) and mediastinoscopy together with sternotomy and thoracotomy. If the lesion is close to manubrium; another option is to reach the lesion by adding manubriectomy to U shaped incision. However transsternal approach is preferred; because it doesn't require double lumen and chest tube; there is less pain with it and the lesions located in thymus left pole are reached more easily through it.

Today there are publications related to intraoperative gamma probe use at the parathyroid adenomas surgery [5]. If thoracoscopic and mediastinoscopic surgery has been preferred; it is possible to quickly define the lesions with gamma probe use; but experience and expertise is needed. In the cases with sternotomy; since tissues containing adenoma that excised totally with mediastinal fat tissue is compared to simultaneously gamma probe use; this seems to be a procedure not requiring a special experience. There is no any randomized controlled trial on which has better surgical outcomes from the cases in which gamma probe were used and sternotomy was performed and the cases in which gamma probe was not used. Due to it requires experience and can not always be found; considering the outcome also; requirement of gamma probe is controversial. However; its contribution to the surgery by experienced persons at the 2nd operation in the cases studied due to hypercalcemia and requiring a reoperation is important [5].

Angioablation is an alternative treatment option except the surgery. Adenomas can be treated by creating ischemia with hyperosmolar contrast agent injection. This method which is generally performed by the radiologists percutaneously; is seen as an alternative method at elective cases and the patients that the surgery can not be done [7]. Mortality at the patients with surgery was performed due to ectopic parathyroid adenoma is low as to be ignored. Kumar et al. have reported that mortality has not been seen at 26 patients with surgery performed due to parathyroid adenoma in the literature between 1996 and 2001 [8]. However morbidity and surgical complication rates differs as to preferred method. Russell et al. [9] have reported the complication such as pleural effusion; pneumothorax and pneumonia by 21% of patients and surgical wound complications by 8%. When the cases analysed in respect of preferred surgical procedure; transsternal approach comes to the front with less pain; not requiring chest tube; easy access to the adenomas located in left tumor pole and short operation time. In VATS method; operation time differs between 40 – 240 minutes according to the surgeon's experience; wound infection is less and there are no complications such as sternal dehiscence; hematoma and mediastinitis [8]. When parathyroid adenoma is excised; it is important that the capsule should be intact and not ruptured. Therefore we preferred transsternal approach in our case.

Beside vital evidence and hemogram; biochemical values also should be monitored closely at postoperative period in the patients operated due to parathyroid adenoma. Ca<sup>+</sup> and phospho-

rus values should be checked at least twice a day as well daily PTH levels. Ca<sup>+</sup> resorption from blood to the bones begins due to rapidly decrease of patients' PTH levels with the operation and reducing of their destructive influence on the bones. In a such case described as hungry bone syndrome; Ca<sup>+</sup> levels are under 8.5 mg/dl and serum phosphate levels are at the normal limits or under 3 mg/dl [10]. In our patient also Ca<sup>+</sup> values had began to decrease postoperatively first day. Then laboratory values returned to normal limits by close monitoring of PTH and Ca<sup>+</sup> levels and appropriate replacement. Patients should be informed on follow-ups after discharging and it should not be forgotten that hypocalcemia or as a sign of insufficient surgery; hypercalcemia may occur.

In conclusion; adenomas that are common cause of primary hyperparathyroidism may be seen at mediastinal as the ectopic location. For those lesions which their localization often can be detected with Tc99m MIBI; although thoracoscopic excision can be performed with the surgeon's VATS experiences increasing recently; yet transsternal approach is the most preferred treatment option. Patients should closely followed-up against the complications may develop; electrolyte monitoring and adequate fluid electrolyte replacement as needed should be done.

#### Competing interests

The authors declare that they have no competing interests.

#### References

1. Thompson NW, Eckhauser F, Harness J. The anatomy of primary hyperparathyroidism. *Surgery* 1982;92(5):814-21.
2. Akerström G, Grimelius L, Johansson H, Lundqvist H. Estimation of the parenchymal-cell content of the parathyroid gland, using density-gradient columns. Preliminary report. *Acta Pathol Microbiol Scand A* 1977;85(4):555-7.
3. Al-Mashat F, Sibiany A, Faleh D, Kary K, Alfi AY, El-Lakany MM. Mediastinal parathyroid adenoma. *Saudi J Kidney Dis Transpl* 2009;20(5):826-30.
4. Moriyama T, Kageyama K, Nigawara T, Koyanagi M, Fukuda I, Yashiro H, et al. Diagnosis of a case of ectopic parathyroid adenoma on the early image of 99mTc-MIBI scintigram. *Endocr J* 2007;54(3):437-40.
5. Uludag M, Isgor A, Yetkin G, Atay M, Kebudi A, Akgun I. Supernumerary ectopic parathyroid glands. Persistent hyperparathyroidism due to mediastinal parathyroid adenoma localized by preoperative single photon emission computed tomography and intraoperative gamma probe application. *Hormones (Athens)* 2009;8(2):144-9.
6. Johnson NA, Tublin ME, Ogilvie JB. Parathyroid imaging: technique and role in the preoperative evaluation of primary hyperparathyroidism. *AJR Am J Roentgenol* 2007;188(6):1706-15.
7. Heller HJ, Miller GL, Erdman WA, Snyder WH 3rd, Breslau NA. Angiographic ablation of mediastinal parathyroid adenomas: local experience and review of the literature. *Am J Med* 1994;97(6):529-34.
8. Kumar A, Kumar S, Aggarwal S, Kumar R, Tandon N. Thoracoscopy: the preferred method for excision of mediastinal parathyroids. *Surg Laparosc Endosc Percutan Tech* 2002;12(4):295-300.
9. Russell CF, Edis AJ, Scholz DA, Sheedy PF, van Heerden JA. Mediastinal parathyroid tumors: experience with 38 tumors requiring mediastinotomy for removal. *Ann Surg* 1981;193(6):805-9.
10. Brasier AR, Nussbaum SR. Hungry bone syndrome: clinical and biochemical predictors of its occurrence after parathyroid surgery. *Am J Med* 1988;84(4):654-60.